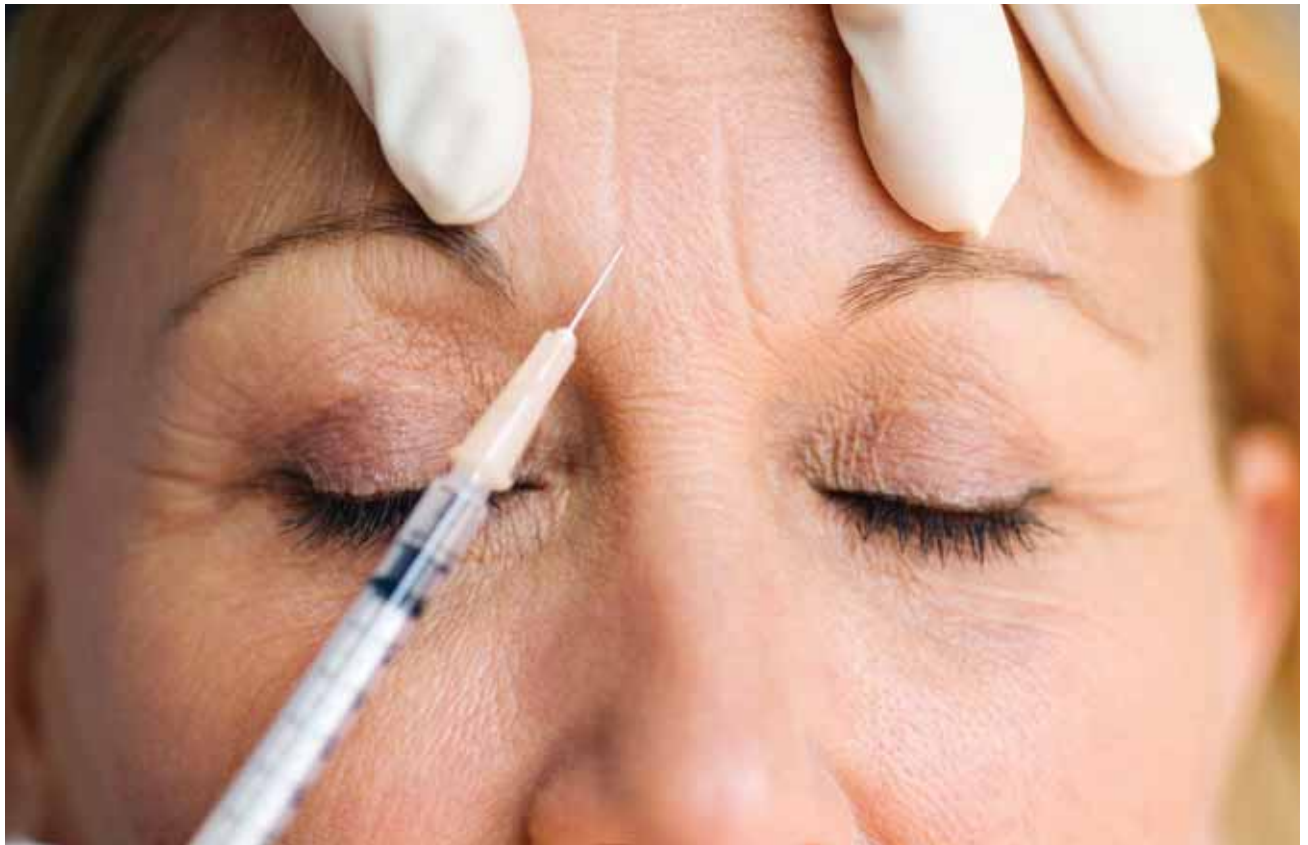



When a **toxin** is a tonic

As well as its cosmetic applications, botulinum toxin can also be used to treat a range of conditions including hyperhidrosis and migraines. **Dr Rohit Kotnis** and **Dr Sonali Kotnis** discuss advanced techniques and options for treatments and facial rejuvenation

Botulinum toxin, popularised for the treatment of wrinkles by **Dr Jean Carruthers**, is the most common aesthetic procedure performed in the UK. Since its introduction, the number of clinical applications has steadily increased. This article focuses on advanced techniques and treatments with botulinum toxin (table 1), which should be performed by experienced cosmetic practitioners.

Facial expression is controlled by the balance between elevator muscles and depressor muscles. Successful facial rejuvenation requires the creation of a new muscular balance that inhibits the activity of certain muscles and relies on other muscles maintaining or increasing their activity. The aesthetic practitioner must provide individual specific treatment. Variation of doses and injection sites is important to achieve this. Prior to treatment, the

aims and expectations of the client should be accurately identified and a plan drawn up to maximise the chances of a successful outcome. An honest approach with realistic expectations is crucial.

Table 1: Techniques and treatments with botulinum toxin

Hyperhidrosis
Migraine
Upper face – eye brow lift, bunny lines, infra-orbital crow's feet
Lower face – nasolabial folds, marionette lines, chin contouring
Neck lines

Headaches are a significant cause of patient morbidity and lead to approximately 5% of total physician consultations

Headaches

Headaches are a significant cause of patient morbidity and lead to approximately 5% of total physician consultations. A more severe form is a migraine in which the patient may have an aura combined with significant headache, vomiting and vertigo. Botulinum toxin is increasingly being used to alter the headache pattern and has proved successful, providing simple guidelines are met.

The first is correct patient selection (table 2) and exclusion of secondary medical causes (table 3). The headache should be accurately localised and a neurological examination performed. Where the neurological examination is abnormal and a secondary cause suspected, referral to a neurologist is advised as safe medical practice prior to any treatment. Patients should be informed that the treatment may not completely alleviate their headaches but should reduce both the frequency and severity.

Botulinum toxin works via both the muscle and nerve/nociceptor (pain) pathways to relieve and prevent headaches. Injections may be given at fixed sites, where the client feels the

pain or a combination of the two. A typical regime is shown in Table 4 with injection sites for the temporalis and occipital muscles in Figures 3-4.

Providing patient selection and expectations are accurate, the client can expect a good result. My clients who suffer from headaches are usually aware that their botulinum toxin treatment is starting to wear off when they notice the return of their headaches before their lines!

Table 2: Patient selection characteristics
Exclusion of medical causes
Failure to respond to conventional treatments
Side effects of previous treatments
Headaches of sufficient severity to affect quality of life
Co-existent neck muscle spasm

Table 3: Causes of headache
Primary
Migraine, tension type, cluster headache
Secondary
Intra-cranial pathology, hypertension, anxiety, endocrine disorders, hypoglycaemic episodes

Table 4: Typical regime for the treatment of headaches
Frontalis – 2.5 to 5 units each site in three sites per side
Corrugator – 2.5 to 5 units each corrugator
Procerus – 4 to 8 units
Temporalis – 5 units in two to four sites
Occipitalis – 10 units each side (optional)

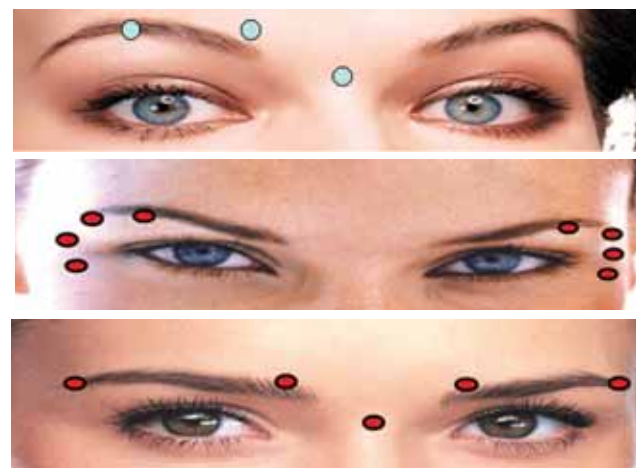


Figure 5: Eyebrow rejuvenation with suggested injection sites; (top) arched brow; (middle) flared brow; (bottom) horizontal brow

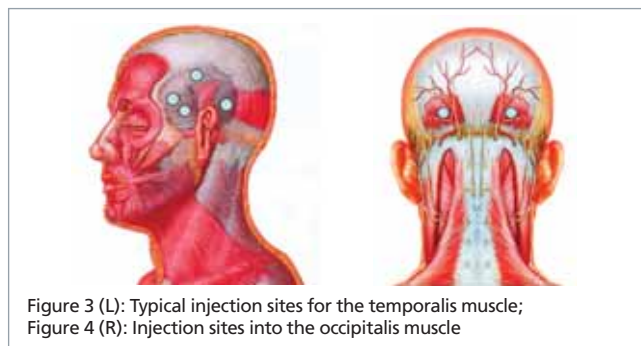


Figure 3 (L): Typical injection sites for the temporalis muscle; Figure 4 (R): Injection sites into the occipitalis muscle

**Upper face
Eye brow lift**

This area is a particular cause of concern for most clients and one that requires thorough preparation—the margin for error is small. It is vital to start by assessing the natural shape of the eyebrow and to look for any pre-existing asymmetry that may require correction. Photographic evidence prior to injecting is important.

The next stage and perhaps the most important is to understand the client’s preference for an eyebrow slope and to plan treatment accordingly. The three main types of eyebrow are the arched brow, flared brow and the horizontal brow (Figure 5).

Bunny lines

These extend from the nasal canthus to the bridge of the nose and can arise secondary to squinting during eye accommodation or become more noticeable following treatment of the glabellar/crow’s feet regions. Treatment of the nasalis muscle and in the transition zone of procerus to nasalis should be considered when assessing patients who require rejuvenation of the upper face.

Injection requires two to four units of Botox (Dysport 5-10 units) into the nasalis on either side, with massage in a medial direction. It is important to be more medial in your injection direction to avoid the levator muscles which could, in turn, lead to lip ptosis.

Infra-orbital crow’s feet

This injection can work well when patient selection is appropriate and in many cases, the lines under the eyes are as much of a

concern as the more recognised crow's feet lines. Poor candidates include those with obvious suborbital fat pads. In this case, relaxing the orbicularis oris muscle leads to the fat pads bulging more prominently resulting in less than satisfactory cosmesis and surgery is the preferred option. Other clients to avoid are those with redundant skin, lid laxity and pre-existing ectropion, as lower lid oedema can arise. The 'snap test' can be used to differentiate lid laxity by pinching the lower eyelid to see how quickly the lid snaps back against the globe.

Inject two units of Botox 4-6mm below the lash margin in the mid-pupillary line. A second injection midway between mid-pupillary line and lateral canthus is often required, but this injection can lead to lateral rounding of the eye.

Lower face
Nasolabial folds

The nasolabial fold is composed of excess skin, the malar fat pad and insertion point of the superficial muscular aponeurotic system (SMAS) into the skin. The malar fat pad slides forward and downward with age thus deepening the fold. Using filler alone in this area may leave the client with fatter looking cheeks. The folds are often prominent when patients are smiling and soften significantly when their face is relaxed. These patients may benefit from injections of one to two units of Botox into the belly of the levator labii superioris alaeque nasi muscle (not the groove). The inferior portion of this muscle is better treated with fillers. Upper lip ptosis can arise from too high a dose and incorrect needle placement.

Peri-oral lip lines

The common complaint is that lipstick moves upwards into the thin grooves. The strong muscle action of orbicularis oris can be reduced using botulinum toxin in all four quadrants. A pleasant side effect is pseudo-augmentation of the lip via an eversion of the vermillion border, which is usually very pleasing to most clients. Inject one to two units of Botox per site, up to four sites symmetrically at or above the vermillion border. Inject into the hillock and not the lines. Do not inject into the columella and avoid the lateral quarter.

Marionette/corner of the mouth lines

These are due to loss of subcutaneous fat, not dynamic muscle contractions. Depressor anguli oris pulls the mouth corner down. Three to five units are injected into each side, into the downward line that reaches the mandible. In my experience, the technique works best when combined with dermafillers.

Chin contouring

Wrinkling on the chin can be improved by injections into the mentalis muscle using one (more commonly) or two injection

sites on each side. The projection of the chin can be improved with relaxation of the over-contracting mentalis (Figure 6). The horizontal mental crease can be treated with the injection of two to three units per side just below the mental crease. Too high a dose can interfere with speech and may lead to drooling. The dimply or popply chin can be treated with 5-10 units per side using one to two injections.

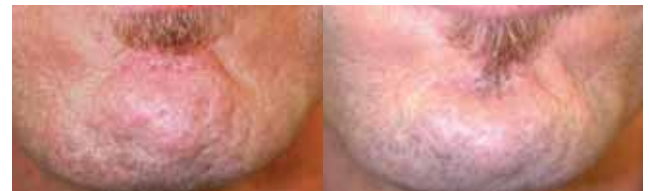

Figure 6: Before (L) and after (R) chin rejuvenation

Neck lines

Botulinum toxin can be used to treat the age-related hypertrophy of platysma with superficial injections to relax the medial and lateral parts of the platysma muscle, which run vertically up the neck region. This can reduce the platysmal bands and soften the horizontal neck lines (Figure 7). In addition, a lifting effect on the lower and mid-face may result. Injections are intradermal in depth, recognising that the platysma muscle is attached to skin. Two to three units are given per injection site, up to a maximum of 50 units. Potential side-effects are dysphagia and dysphonia. The treatment of neck lines is a very satisfying procedure and one which clients really benefit from.



Figure 7: Before (L) and after (R) injection of botulinum toxin into neck lines

Solutions

This article has addressed some advanced applications of botulinum toxin, which together with the conventional injections into the forehead, frown and crow's feet regions, can lead to a significant improvement in facial rejuvenation. In the case of hyperhidrosis and headache treatments, clients will be surprised with these indications and very pleased with the results. I have found that my relationship with my clients has improved significantly using some of these techniques. The cosmetic practitioner is, however, advised to attend a recognised training course prior to embarking on advanced techniques.

Dr Rohit Kotnis Bsc, MBChB, MRCS is an advanced Botox tutor at Dermis Deep, Birmingham. Dr Sonali Kotnis MBBS is a medical aesthetic practitioner.

{ A side-effect of treating peri-oral lip lines is pseudo augmentation of the lip, which can be pleasing to patients }